Retículo Endoplásmico - Liso

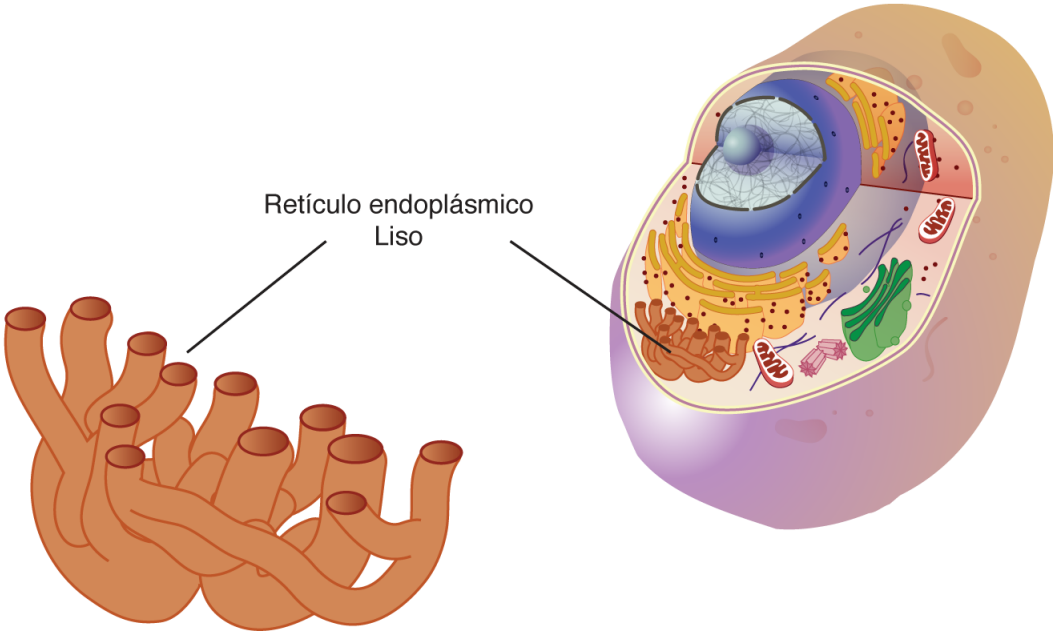

Illustration by Darryl Leja, NHGRI